

## Hemorrhage DR Detection using Image Processing

Rahul Shandilya<sup>1</sup>, Nagma Sheikh<sup>2</sup>, Rahul Dhutur<sup>2</sup>

*M. Tech (Communication) Scholar, Dept. of Electronics & Telecommunication Engg., TGPCET, Nagpur.*

<sup>2</sup>*Department of Electronics & Communication Engg TGPCET, Nagpur University Nagpur,India*

<sup>3</sup>*Department of Electronics & Communication Engg TGPCET, Nagpur University Nagpur,India*

---

**Abstract:** Hemorrhages are one of the diabetic retinopathy diseases which affect the retinal part. It Occurs in the deeper layers of the retina and are often called 'blot' hemorrhages because of their round shape. Abnormal new blood vessels form at the back of the eye as a part of Proliferative Diabetic Retinopathy (PDR).

Hence the new blood vessels are weak that causes blur vision.

A retinal hemorrhage may be caused cardiovascular disease, retinal vein occlusion (a blockage of a retinal vein), or diabetes mellitus (which causes small fragile in blood vessels which are easily damaged). The presence of hemorrhages in the retina is the main symptom of diabetic retinopathy. The number and shape of hemorrhages is used to identify the severity of the disease. The objectives of this study are to detect blood vessel, identify hemorrhages and classify different stages of diabetic retinopathy into traditional, moderate and non-proliferative diabetic retinopathy (NPDR).

**Keywords:** Hemorrhage, Diabetic retinopathy, image processing.

---

### I. Introduction

In recent times, everywhere in the world have been faced with an increase in age and society associated diseases like diabetes. The World Health Organization (WHO) has estimated that diabetic retinopathy is accountable for 4.8% of the 37 million instances of blindness in the course of the world. It had been identified and regular as one of the major cause of blindness within the u . S . A . whilst the diabetic disorder isn't always nicely dealt with and managed. Early detection and analysis have been recognized as one of the manner to obtain a discount in the percentage of visible impairment. Human eye may also exaggerated by way of exclusive eye diseases. Among them, retinal disorders can be detected thru the retinal fundus photograph. The retina is a sensitive a part of the eye which senses the vision records and sends it to the brain. Diabetes is the major motive for visible loss. More emphasis on ordinary scientific test with the usage of unique centers for detection and tracking of the diabetics illnesses such as diabetic retinopathy which occur on the retinal part of the attention. A retinal hemorrhage is usually diagnosed with the aid of the use of a fundus camera to be able to have a look at the inner of the eye. A fluorescent dye is regularly injected into the affected person's bloodstream in advance so the administering ophthalmologist can have a greater detailed exam of the blood vessels inside the retina. In earlier days, human specialists manually perceive the symptoms of diabetic retinopathy inthe digital coloration fundus pictures of retina all for the assist of ophthalmoscopy or fundus photography. It requires extraordinarily skilled and professional specialists to perform prognosis. In such guide grading, because of the increasing variety of humans with diabetes, detection of DR symptoms is found to be a heavy and inaccurate task while screening a large number of pix. By growing the work stress which masses at the employees that could lead to increase the diabetes screening activities. A lot of strategies had been cautioned and identified for decreasing the pressure caused by the steady checkup. Screening related sports which use of scientific digital picture signal processing for prognosis of diabetes associated diseases like DR through the use of pictures of the retina. Diabetic Retinopathy is a first-rate disease which may also occur to a affected person who having diabetic mellitus. Hemorrhages and exudates are the trouble of Diabetic Retinopathy which occurs at the retina. Diabetes is nothing but a sickness of metabolism. The power required for the frame which is generated from glucose that produces a end result of meals digestion. Digested meals enters the frame flow with the useful resource of a hormone called "insulin" that is produced with the aid of the pancreas. It is an organ that lies near the stomach. During eating, the pancreas robotically produces the proper quantity of insulin. It allows glucose absorption from the blood into the cells. In individuals with diabetes, pancreas either produces too little or no insulin or the cells do no longer react nicely to the insulin this is produced. The buildup of glucose inside the blood, overflows into the urine after which passes out of the frame. Therefore, the body loses its most important source of fuel despite the fact that the blood contains large amounts of glucose.

## II. Literature Review

The authors delivered new technique for detection of hemorrhage by using 3 steps, doing away with noise from fundus image, vessel removal, disposing of the fovea and detection shape, area, aspect ratio, density and mean intensity [1] To deal with two issues in detecting pink lesions from retinal fundus pictures. To cope with false detections on blood vessels, new filter out is proposed which distinguish between pink lesions and blood vessels [2]. Diabetic Retinopathy is the Leading motive of blindness. It is the major problem in worldwide. Recent health studies estimates that fifty four million American have diabetes and most of them don't realize it. WHO screen that 347 million human beings have this diabetes worldwide? As many as 25,000 human beings have lose their vision due to diabetic retinopathy each year [3]. Diabetic retinopathy is produced through the retinal micro vasculature. Blindness may additionally look as a result of unchecked and intense cases of

diabetic retinopathy. Manual examination of fundus images to check morphological modifications in microaneurysms, exudates, blood vessels, hemorrhages, and macula is a very timeconsuming and monotonous work [4]. This paper is examined on DRIVE and DIARETDB1 databases and is compared with the other approaches. The segmentation technique carried out the common accuracy of 98.7% while the diseased photo turned into detected with 99% accuracy [5].

This paper developed an computerized technique for detection of hemorrhage. They used template matching technique for the detection of hemorrhage. For detection of right length of hemorrhage vicinity growing segmentation used. This have a look at is enhancing automatic hemorrhage detection technique to assistance diagnosis of diabetic retinopathy. The sensitivity for the detection of abnormal instances have been 80% and 90% respectively [6].

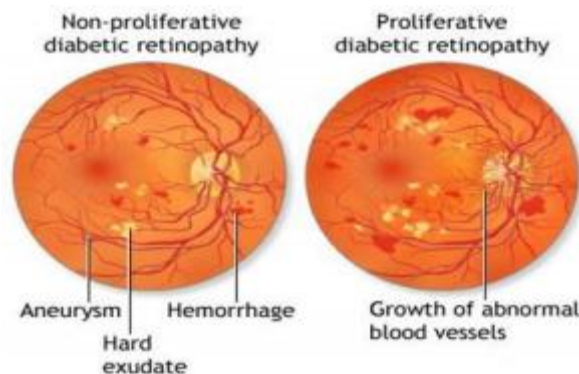


Figure 2: kinds of Diabetic Retinopathy (a) Proliferative DR.(b) Non-proliferative D

Two sorts of DR are shown in Fig.1. The levels of Retinopathy are Non-Proliferative and Proliferative. Earlier level is Non- Proliferative Diabetic Retinopathy (NPDR) in which signs and symptoms will be slight or non-existent. Some of the Non-Proliferative Diabetic Retinopathy lesions include Micro aneurysms, Exudates and Hemorrhages.

Retinal hemorrhage is useful to discover NPDR. So, in advance detection of NPDR is beneficial to improve automatic screening system.

NPDR, structural damage may also occur on the back of the eye inflicting the blood vessels to rupture. Second, superior or intense level is Proliferative Diabetic Retinopathy (PDR) takes place due to new blood vessel beginning to grow in the attention that are fragile and can bleed which reasons Blindness. At first, the humans struggling with DR may observe no changes in their vision. It could worsen through the years and threaten their appropriate vision. Treatment for diabetic retinopathy depends on the degree of the sickness and is directed.

## III. Methodology

Algorithm:

Step 1: Read enter retinal photo and extraction of inexperienced channel

Step 2: Adaptive histogram equalization of the image to enhance the first-class of image.

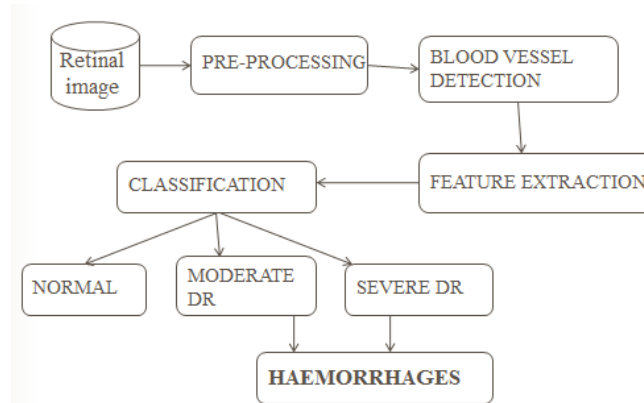
Step 3: Background removal the use of histogram equalization.

Step 4: Removal of salt and pepper noise the usage of Median Filtering.

Step 5: Convert the photo obtained within the preceding step into binary the image using thresholding operation.

Step 6: Shape based parameters i.e. Area, Eccentricity and perimeter become used for extraction of the red lesions.

Step 7: Removal of fake positives the use of histogram analysis.



In this proposed method the input is a RGB scale retinal photograph. The most critical feature of a RGB photo is its 3 unbiased channels namely red, green and blue. Fig.3 indicates a RGB image and its three special components. It is truly obvious from the three channels of the RGB picture that the green channel includes the maximum information approximately the crimson lesions. Therefore, the green channel of the RGB scale retinal picture is used for further processing. Proposed system includes 3 modules which can be A) Pre-processing the retinal picture, B) Blood Vessel Detection C) Feature Extraction and C) Classify the output by classifier technique

A. Pre-processing The enter of the automated machine is coloration fundus retinal picture which is taken from internet. This stage corrects the trouble of illumination variant of the photo taken. The following pre-processing steps in my automated machine consist of are:

i)Resizing: The retinal gray pictures The input retinal pictures are resized into small pix. It is in particular to avoid overloading and time consumption.

i) Color to green channel extraction : To convert RGB coloration fundus photos into green channel conversion.

ii) Median Filter The median filter out is a nonlinear clear out, which can reduce impulsive distortions in an photograph and without too much distortion to the edges of such an photo. It is an effective approach that of suppressing remoted noise without blurring sharp edges. Median filtering operation replaces a pixel by the median of all pixels inside the community of small sliding window. The advantage of a median filter is that it is very sturdy and has the capability to clear out only outliers. Noisy pixels are seemed with the background information. Hence we want to get rid of noisy pixels before evaluation enhancement by using the use of a median clear out.

Iv) Adaptive histogram technique

Adaptive histogram is used to enhance the “comparison” and to improve the first-rate of retinal picture. One of the issues relates to fundus snap shots is uneven illumination. Some regions of the fundus snap shots are appear as brighter than the other. At the middle of the photograph are continually properly illuminated. Hence, it seems very bright whilst they far far from the poorly illuminated region and also seem as very dark. If the illumination decreases then the gap from the middle of the pix also are increases. Many strategies had been attempted to resolving this trouble of un-even illumination, among that's the usage of Adaptive Histogram Equalization Method (AHEM). AHEM gives better performance; higher processing velocity and work nicely for all photographs are of different sizes, for this reason the motive for it being used as approach of correcting un-even illumination. A variant of adaptive histogram equalization known as Contrast Limited Adaptive Histogram Equalization (CLAHE). Images processed with CLAHE are of greater natural look and facilitate the comparison of different regions of an image. To complements the evaluation of the gray scale pix by way of transforming the values the usage of comparison-restricted adaptive histogram equalization (CLAHE). The essential objective of this approach is to define a factor transformation inside a local fairly big window. By assuming the assumption of intensity value within it is a stoical representation of local distribution of intensity cost of the whole photograph. The neighborhood window is assumed to be unaffected through the slow variant of depth among the photograph facilities and edges. The factor transformation distribution is localized round the mean depth of the window and it covers the complete intensity range of the photo

### **B Blood Vessel Detection**

After improving the evaluation of the photo, median clear out is used to cast off the noise. The designed matched filter out is applied on the photograph to stumble on the blood vessels. Finally, a binarised photo is obtained by way of thresholding.

A matrix was generated to shop the number of matched filter which become responsible for detecting that precise pixel of the blood vessel. The grey degree value of the pixels in a selected course of detection turned into multiplied through a element. The value was then checked to be above threshold level. For 0°, 15° and 180°, pixels within the horizontal path have been checked; for 30°, 45° and 60°, pixels inside the 45 degree and 225 degree directions have been checked; for 75°, 90° and 105°, pixels in vertical path and for 120°, 135° and 150°, pixels in 135 diploma directions were checked. If grey price multiplied by using a issue became greater than the threshold, then that pixel turned into counted as blood vessel. Finally, the blood vessels are extracted pixel by using pixel.

### **C. Feature Extraction**

In feature extraction, Texture evaluation used to extract feature values from the input pics. These features are used to tries quantify intuitive qualities which can be defined in terms of rough, smooth and silky as a characteristic of spatial version are shown in pixel intensities. Texture analysis can be useful when gadgets in an image are more characterized via texture than via intensity.

It includes entropy, entropy clear out, grey level co-prevalence matrix, range.

**D. Classification** The choice for green category depends on the size of the dataset. Whenever the dataset is few, low variance classifier like Naive Bayes may be used. But, inside the case of large dataset, we need a excessive variance and coffee bias classifier along with KNN and Support Vector Machine (SVM). I will prefer classification of hemorrhages on the basis of vicinity and size of the pixels of photograph that's extracted during feature extraction of an image, because it provides extra accuracy on a larger dataset.

## **IV. Conclusion**

Medical imaging is education discipline with the help of digital image processing. It provides medical guide in medical disorder analysis. The recommend set of rules is layout for detection of hemorrhage at early stage. The proposed automated gadget used to discover patients having diabetic retinopathy the use of fundus images.

## **References**

- [1]. Dolly Sahu, Sachin Meshram, "Automatic Detection of Hemorrhages Using Image Processing Technique", International Journal of Engineering Sciences & Research Technology, ISSN: 2277-9655, 2016.
- [2]. Ruchir Srivastava, Lixin Duan, Damon W. K. Wong, Jiang Liu, Tien Yin Wong, "Detecting retinal microaneurysms and hemorrhages with robustness to the presence of blood vessels", Elsevier, computer methods and programs in biomedicine 138, 2017.
- [3]. Falguni Thakkar, Rajvi Parikh, "A Survey on Automatic Detection of Diabetic Retinopathy Exudates from Retinal Fundus Images", International Journal of Advanced Research in Computer and Communication Engineering, ISSN (Online) 2278-1021, Vol. 5, Issue 5, 2016.
- [4]. Javeria Amin, Muhammad Sharif, and Mussarat Yasmin, "A Review on Recent Developments for Detection of Diabetic Retinopathy", Hindawi Publishing Corporation Scientifica Volume 2016, 6838976, 2016.
- [5]. Ishmeet Kaur & Lalit Mann Singh, "A Method of Disease Detection and Segmentation of Retinal Blood Vessels using Fuzzy C-Means and Neutrosophic Approach", Imperial Journal of Interdisciplinary Research (IJIR), ISSN: 2454-1362, Vol-2, Issue-6, 2016.
- [6]. Reshma M. M., Chavan M. S., "Detection of Hemorrhage from Fundus Images using Hybrid Method", International Journal of Computer Applications (0975 – 8887), Volume 107 – No 12, 2014. I. S. Jacobs and C. P. Bean, "Fine particles, thin films and exchange anisotropy," in Magnetism, vol. III, G. T. Rado and H. Suhl, Eds. New York: Academic, 1963, pp. 271–350.